

The Versatility of the Medial Thigh Flap for Reconstruction of Post-Fournier's Gangrene Complex Perineoscrotal Defects

Wael M. Ayad, M.D.; Osama A. Al-Shahat, M.D.; Ehab Zaid, M.D.;
Tarek Albanooby, M.D. and Essam Taman, M.D.

The Departments of Plastic & Reconstructive Surgery, Al-Azhar and Tanta Universities.

ABSTRACT

This study aims to describe the use of the medial thigh flap for reconstruction of perineoscrotal defects. Nine medial thigh fasciocutaneous flaps performed (five unilateral and two bilateral) for seven adult male patients. The base of the flap designed to be over the femoral triangle, the dominant pedicle located at the apex of the femoral triangle 6-8cm below the inguinal ligament and the exact site was detected preoperatively by Doppler examination, the width of the flap ranged from 7-10cm, while the length ranged from 17-25cm, the donor side closed directly in all cases.

All flaps survived well, with the exception of partial distal necrosis in two cases, which managed conservatively in one case, while in the other case debridement and minimal advancement of the flap done. In conclusion, the medial thigh fasciocutaneous flap offers a good option for perineoscrotal defects. The flap provided a single stage, stable well vascularised soft tissue coverage in our patients with no significant complications.

INTRODUCTION

Perineoscrotal (Fournier's) gangrene is a rare potentially fatal clinical entity¹. It is characterized by progressive spread of necrosis in the skin and subcutaneous tissue combined with severe systemic infection [15]. Following aggressive surgical debridement, major scrotal and perineal defects with exposed testes are a challenge for reconstructive surgeons [13,21].

Numerous techniques have been described for reconstruction of these defects including split thickness skin grafts [12,14], muscle flaps (e.g. Gracilis flap) [10,11] and fasciocutaneous flaps (e.g. pudendal flap [5,6], perineal flap [4], anterolateral thigh flap [22], deep inferior epigastric perforator flap [24] and anteromedial thigh flap) [25-27].

This study presents the author's experience using the medial thigh flap for coverage of scrotal and perineal defects after debridement of Fournier's gangrene.

PATIENTS AND METHODS

Between July 2007 and March 2010 medial thigh flap was performed in seven male adult patients. Their mean age was 42 (range 33 to 52 years). All patients presented with soft tissue defects of the scrotal and perineal areas after extensive multiple debridement sessions for Fournier's gangrene.

Broad spectrum systemic antibiotics were given and continued for 5 days postoperatively.

Nine medial thigh fasciocutaneous flaps were performed (five unilateral and two bilateral). Patients were followed for 3-18 months postoperatively.

Anatomical bases of the flap:

The medial thigh flap located along the medial aspect of the thigh, based on a septocutaneous branch of the femoral artery at the apex of the femoral triangle, the axis of the flap extends from the apex of the femoral triangle toward the medial femoral condyle. The skin territory of the flap extends from the inferior aspect of the femoral triangle to the junction of the middle and distal thirds of the medial thigh. The lateral borders of the flap located between the lateral edge of the adductor longus and the medial edge of the rectus femoris muscle.

Surgical technique:

All patients done under general anesthesia with orotracheal intubation in lithotomy position. As previously described in the literature [2,7], the axis of the flap was drawn as a line from the pubic tubercle to the medial femoral condyle. The base of the flap designed to be over the femoral triangle. The dominant pedicle located at the apex of the femoral triangle 6-8cm below the inguinal ligament

and the exact site was detected preoperatively by Doppler examination. The width of the flap ranged from 7-10cm according to the redundancy of the thigh skin, while the length ranged from 17-25cm tapered distally to facilitate direct closure of the donor site. Elevation of the flap begin distally in the subfascial bloodless plane over the muscles, started from distal to proximal until few centimeters distal to the pedicle followed by careful dissection of the pedicle and then rotation of the flap as a hammock to cover the testicles and the perineal area and creating a scrotum with tension free inset. Direct closure of the donor site with suction drain

done in all cases. A scrotal support used post-operatively for 3 weeks until dependent edema subsided.

RESULTS

All flaps survived well, with the exception of partial distal necrosis in two cases. This was managed conservatively in one case, while the other case needed debridement and minimal advancement of the flap.

Infection of the donor site suture line occurred in one case which managed by frequent dressing.

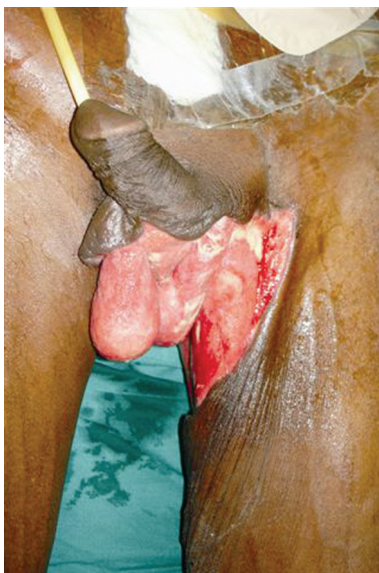

Fig. (1-A): A 37 year old male patient known to have uncontrolled diabetes, developed Fournier's gangrene. The areas involved was the base of the penis, scrotum, perineum, medial aspect of the upper left thigh and medial aspect of the left gluteal area.

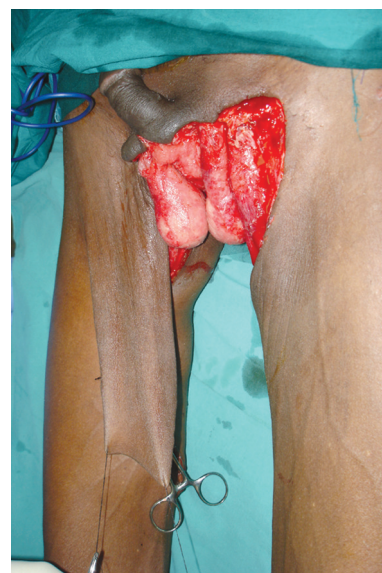

Fig. (1-B): Total wound debridement & preparation and the Rt. Medial thigh flap harvested (11X25cm).

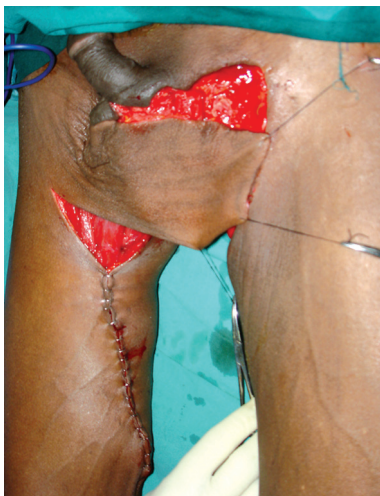

Fig. (1-C): Rotation of the flap over the defect.

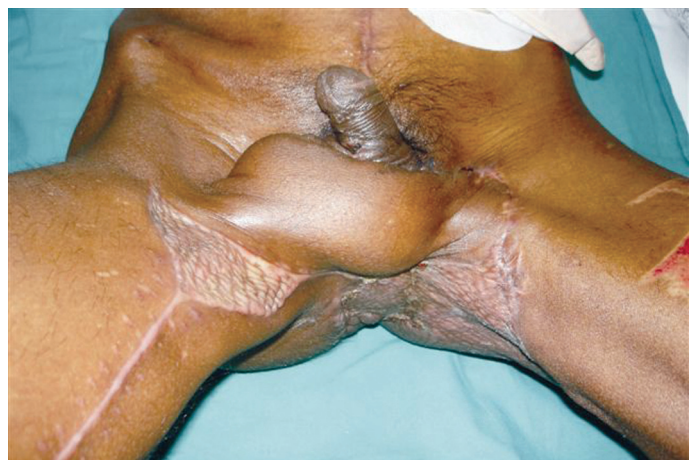

Fig. (1-D): The final result after healing of the wounds of the flap and the skin grafts.

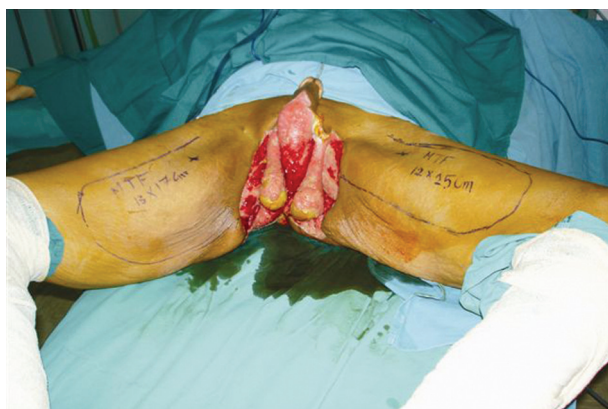

Fig. (2-A): A 48 year old male diabetic patient developed Fournier's gangrene with extensive soft tissue defect involving both testes, proximal penis, perineum and parts of the medial aspect of both upper thighs.

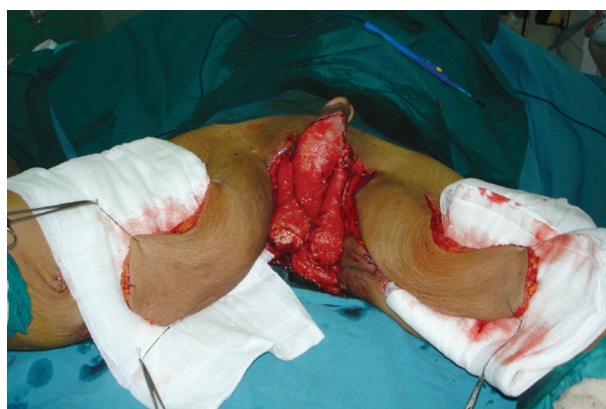


Fig. (2-B): Complete wound debridement, bilateral medial thigh flaps harvested, measuring 13 X 17cm (right) and 12 X 25 (left).

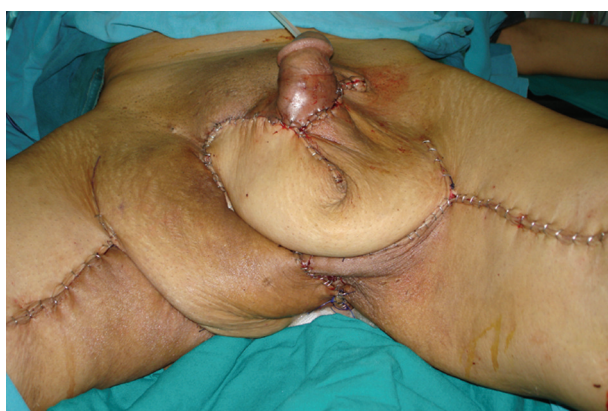

Fig. (2-C): Insitting of the flaps over the defects, the Lt. flap covered the penoscrotal area and the Rt. flap covered the perineum with direct closure of the donor sites.

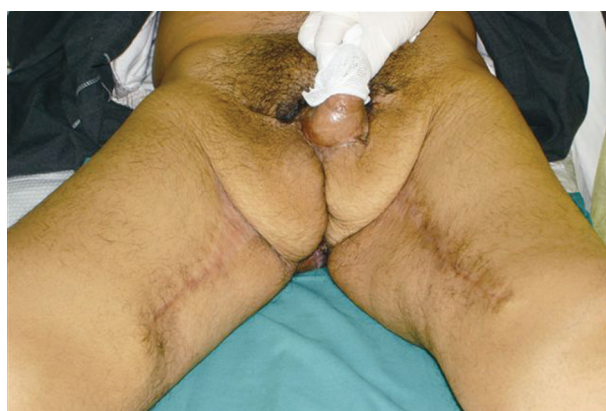

Fig. (2-D): Final results, 8 weeks after healing of the flaps and the donor sites wounds.

DISCUSSION

Scrotal reconstruction after Fournier's gangrene remains a major challenge. Reconstruction of the scrotum is important for functional, cosmetic and psychological reasons [22]. The ideal reconstructive approach would seem to incorporate the following flap features: A single stage procedure, excellent flap reliability, sensate flaps with a potential for normal function, minimal donor-site morbidity and simplicity [19,20].

The medial thigh flap is a reliable fasciocutaneous flap which can be done in reasonably short operative time to cover difficult defects in those critical patients. The donor scar is hidden in the medial aspect of the thigh.

We have transposed the flap medially and used it to cover scrotal, penile, perineal and proximal thigh defects. The exact limitations on width and length of the flap are unknown, but the rich su-

prafascial plexus in this area allows safe elevation of flaps with a 3:1 length-to-width ratio [17], our largest flap measured approximately 10cm X 25cm.

Wang [18] described the vascular supply and innervation of the medial thigh fasciocutaneous flap.

Hallock [7] reported the same flap for scrotal reconstruction following Fournier's gangrene.

Although Gracilis musculocutaneous flap share the same cutaneous territory and the donor site defect, medial thigh fasciocutaneous flap has the advantage of being easier and faster to raise, less bulky, easier to transpose and provides thin pliable skin [3]. In addition, elevating the medial thigh flap does not preclude the use of a Gracilis muscle flap, which may be raised on its own vascular pedicle at the same or later procedure [18]. Other Pedicled thigh fasciocutaneous flaps have been described, though they appear less versatile than the medial

thigh flap as the laterally based superomedial thigh flap, which is raised on the proximal medial thigh [8]. Hayashi and Maruyama [9] used an anteromedial thigh fasciocutaneous flap for reconstruction of the groin and lower abdominal wall, Hupkens et al. [23] classified the anteromedial thigh perforators anatomically. Song [16] have previously described its use as a free flap for reconstruction of the neck and forearm and Yu [22] used the anterolateral thigh fasciocutaneous island flap in Perineoscrotal reconstruction. This is more difficult to dissect, more bulky and it's far from the defect.

Conclusion:

The medial thigh fasciocutaneous flap offers a good option for Perineoscrotal defects. The flap provided a single stage, stable, well vascularized soft tissue coverage in our patients with no significant major complications.

REFERENCES

- Atakan I.H., Kaplan M., Kaya E., Aktoz T. and Inci O.: A life-threatening infection: Fournier's gangrene. *Int. Urol. Nephrol.*, 34: 387-392, 2002.
- Baek S.M.: Two new cutaneous free flaps: The medial and lateral thigh flaps. *Plast. Reconstr Surg.*, 71: 354-365, 1983.
- Bostwick J., 3rd, Hill H.L. and Nahai F.: Repairs in the lower abdomen, groin, or perineum with myocutaneous or omental flaps. *Plast Reconstr Surg.*, 63: 186-194, 1979.
- Core G.B., Bite U., Pemberton J.H. and Petty P.M.: Sliding V-Y perineal island flaps for large perianal defects. *Ann. Plast. Surg.*, 32: 328-331, 1994.
- Coruh A., Akcali Y., Ozcan N. and Ekmekcioglu O.: Modified pudendal thigh flap for perineoscrotal reconstruction: A case of Leriche syndrome with rapidly progressing Fournier's gangrene. *Urology*. 64: 1030, 2004.
- El-Khatib H.A.: V-Y fasciocutaneous pudendal thigh flap for repair of perineum and genital region after necrotizing fasciitis: Modification and new indication. *Ann. Plast. Surg.*, 48: 370-375, 2002.
- Hallock G.G.: Scrotal reconstruction following Fournier's gangrene using the medial thigh fasciocutaneous flap. *Ann. Plast. Surg.*, 24: 86-90, 1990.
- Har-Shai Y., Hirshowitz B., Marcovich A., Eliachar I. and Peretz B.A.: Blood supply and innervation of the superomedial thigh flap employed in one-stage reconstruction of the scrotum and vulva-an anatomical study. *Ann. Plast. Surg.*, 13: 504-510, 1984.
- Hayashi A. and Maruyama Y.: The use of the anteromedial thigh fasciocutaneous flap in the reconstruction of the lower abdomen and inguinal region; a report of two cases. *Br. J. Plast. Surg.*, 41: 633-638, 1988.
- Ioannovich J., Kepenekidis A., Stamatopoulos K. and Matar N.: [Use of gracilis musculocutaneous flap in tissue loss caused by Fournier's gangrene. Apropos of 4 cases]. *Ann. Chir. Plast. Esthet.*, 43: 58-63, 1998.
- Lee Y.T. and Lee J.M.: Gracilis myocutaneous flap for the coverage of an extensive scrotoperineal defect and protection of the ruptured urethra and testes. *Yonsei. Med. J.*, 31: 187-191, 1990.
- Maguina P., Palmieri T.L. and Greenhalgh D.G.: Split thickness skin grafting for recreation of the scrotum following Fournier's gangrene. *Burns.*, 29: 857-862, 2003.
- Monstrey S., Blondeel P., Van Landuyt K., et al.: The versatility of the pudendal thigh fasciocutaneous flap used as an island flap. *Plast. Reconstr Surg.*, 107: 719-725, 2001.
- Nikhare S.N. and Kura M.M.: Split-thickness skin grafting: A novel approach in the treatment of Fournier's gangrene. *Indian J. Dermatol. Venereol. Leprol.*, 72: 159-160, 2006.
- Nomikos I.N.: Necrotizing perineal infections (Fournier's disease): Old remedies for an old disease. *Int. J. Colorectal Dis.*, 13: 48-51, 1998.
- Song Y.G., Chen G.Z. and Song Y.L.: The free thigh flap: a new free flap concept based on the septocutaneous artery. *Br. J. Plast. Surg.*, 37: 149-159, 1984.
- Turley C.B., Cutting P. and Clarke J.A.: Medial fasciocutaneous flap of thigh for release of post-burn groin contractures. *Br. J. Plast. Surg.*, 44: 36-40, 1991.
- Wang T.N., Whetzel T., Mathes S.J. and Vasconez L.O.: A fasciocutaneous flap for vaginal and perineal reconstruction. *Plast. Reconstr. Surg.*, 80: 95-103, 1987.
- Wee J.T. and Joseph V.T.: A new technique of vaginal reconstruction using neurovascular pudendal-thigh flaps: A preliminary report. *Plast. Reconstr. Surg.*, 83: 701-709, 1989.
- Woods J.E., Alter G., Meland B. and Podratz K.: Experience with vaginal reconstruction utilizing the modified Singapore flap. *Plast. Reconstr Surg.* 90: 270-274, 1992.
- Young W.A. and Wright J.K.: Scrotal reconstruction with a rectus abdominis muscle flap. *Br. J. Plast. Surg.*, 41: 190-193, 1988.
- Yu P., Sanger J.R., Matloub H.S., Gosain A. and Larson D.: Anterolateral thigh fasciocutaneous island flaps in perineoscrotal reconstruction. *Plast. Reconstr Surg.*, 109: 610-616, discussion, 617-618, 2002.
- Pieter Hupkens, Bram Van Loon, Gert-Jan Lauret, et al. Anteromedial thigh flaps : An anatomical study to localize and classify anteromedial thigh perforators. *Microsurgery* 30 (1) 43-49, 2010.
- Zeng A., Xu J., Yan X., You L. and Yang H.: Pedicled deep inferior epigastric perforator flap: An alternative method to repair groin and scrotal defects. *Ann. Plast. Surg.*, 57 (3): 285-288, 2006.
- Mohammed Abd El-mageed: Evaluation of the anteromedial thigh fasciocutaneous flap for scrotal reconstruction, *Egypt J. Plast. Reconstr Surg.*, 31 (2) 149-155, 2007.
- Ferreira P.C., Reis J.C., Amarnate J.M. et al.: Fournier's gangrene: A review of 43 Reconstructive cases. *Plast. Reconstr Surg.*, 119 (1): 175-184, 2007.
- Higazi M., Ayad H. and Shalaby H.: The use of fasciocutaneous flaps in the reconstruction of groin and trochanteric defects. *Annals of burns and fire disasters*, 8 (4), 1995.